

# SPLINTING AVIAN FRACTURES



Rebecca Duerr DVM MPVM  
*International Bird Rescue Research Center*  
*Cordelia, CA*

# TABLE OF CONTENTS

<u>Section</u>	<u>Page</u>
• Considerations for wild bird care	2
• Glossary of terms	2
• Physical examination	3
• Before beginning the splint	4
• Compound fractures	5
• Prognoses of typical fractures	6
• The avian skeleton	10
• Examining the wing for possible fractures	11
• Splinting fractures of the wing: Humerus or radius/ulna fractures with support	12
• Splinting fractures of the wing: Metacarpal fractures with support	14
• Metacarpal wrap	15
• Calcium supplementation for fractured birds	15
• Slit wing wrap	16
• Examining the leg for possible fractures	17
• Splinting the femur: To immobilize prior to surgery or as the only treatment	18
• Tibiotarsus: making the splint	20
• Tibiotarsus: applying the splint	21
• Splinting the tarsometatarsus	22
• Splinting the foot—applying a shoe	23
• Mallards: walking/swimming splint for tarsometatarsus fractures	25

## Considerations for wild bird care

Treating wild birds with fractures requires the consideration of a number of factors that are not issues in treating domestic pets. First and foremost, each bird must be fit to be released when healed; even with raptors, available placement for disabled birds is a rare thing. It is even difficult to place charismatic species such as eagles. Consequently, reality (and usually rehabilitation licensing) dictates that a bird with an injury that will render it unable to fly or forage should be humanely euthanized. It is both illegal and inhumane to keep most wild birds as pets.

Wild birds, especially if they are adults, are subject to tremendous stress while in captivity; not only are they likely to perceive caregivers as predators, but they are prone to damaging themselves against their caging in efforts to get away. If the bird breaks its primary feathers in the caging, this will automatically add at least three weeks to its stay in captivity, possibly more than a year if the bird is a larger species. Adult birds also do not deal well with being immobile; they often become depressed and unable or unwilling to eat, which leads to force feeding, which leads to more stress, and things can deteriorate from there. Adult birds are unlikely to self-feed without proper daylight-level lighting, so keeping a bird calm by having it in dim light has its problems too.

As a result of these issues, all splints should be designed with minimal restraint in mind. It is not necessary in many cases to fully restrain the joint above and below the break, but rather merely the bone fragment on either side of it. This serves to reduce the post-fracture joint stiffness that results from more restrictive splints, and hence the bird will be ready for release sooner. Your goal should be to make such a fabulous splint that the bird can go about its business while being able to use its broken limb as normally as possible while it is healing. Weight-bearing on a fracture also encourages the body to repair the fracture faster.

Most splints presented here are the result of the years of collective experience of the staff and volunteers of Wildlife Rescue Inc in Palo Alto CA. Others are the inventions of the author. Bear in mind that splinting techniques are not engraved in stone. Don't be afraid to try a new idea to fix an unusual problem, but try to not inflict extra stress on the patient while you experiment. Always have a good idea what you are doing before handling the patient, and be sure to let them rest if they are becoming stressed during the process.

### Glossary of terms

**Simple Fracture:** A break in a bone without an accompanying wound at the fracture site.

**Compound or Open Fracture:** A break where the bone has penetrated the skin to the exterior, or the wound that broke the bone has exposed the broken ends.

**Comminuted Fracture:** Bone is crushed or splintered.

**Multiple Fracture:** Bone is broken in more than one place.

**Impacted Fracture:** A break in which one broken fragment is firmly driven into the other.

**Greenstick Fracture:** A break in which the bone is not broken all the way through.

**Capillary Fracture:** A break that appears as a fine hair-like line on x-ray, with the bone not displaced from its normal position.

**Pathologic Fracture:** A break due to abnormally weak bone structure, such as from dietary deficiency or other disease. Metabolic bone disease (MBD) is an example of this.

Transverse, Oblique, Spiral: Terms used to describe the direction or shape of a fracture.

Callus: Enlarged fibrous and boney bridge that forms during the healing of a fracture. The bridged area is remodeled as healing is completed and is ultimately replaced by true bone. The better the fracture fragments are aligned, the smaller the callus will be. A callus may interfere with joint function if the fracture is close to the joint. The closer the break is to a joint the better the alignment needs to be.

Mal-union: Occurs when the body repairs the fracture with the bones in the wrong position.

Non-union: A failed healing. This occurs when the body has not been able to build a bridge between broken bone fragments. This usually occurs when the fragments are not close enough together due to poor alignment or when the fracture is infected or blood supply is damaged.

Reduction of the Fracture: The act of pulling gently at the joint beyond the fracture to reduce the overlap of the broken ends; used when necessary to bring the bone ends into a more normal position when applying a splint

Luxation: When the bones are not broken but are displaced from the joint, this entails substantial damage to the ligaments that normally stabilize the joint.

### Begin with a careful examination and evaluation

1. Any bird suffering from stress, shock, severe dehydration, or active bleeding should be treated for these life-threatening conditions prior to splinting. The bird must also be calm and warm in order to have the best chance of surviving the stress of splinting. Use soft toweling to arrange the bird comfortably such that any fractures do not become worse while you are waiting to see if the bird will be stable enough to splint (e.g. do not leave a bird with a leg fracture sitting on a hard flat surface). For most songbirds of any age, placing them in an appropriate nest-type support works well. Handle the bird as little as possible.
2. Before beginning the physical exam, critically look at the bird to visualize problems from the way the bird is holding its limbs. With experience, you will be able to spot the location of some fractures just by looking at the bird. This also allows you to spot which bones are NOT broken.
3. Catch the bird quickly and confidently, immediately immobilizing the limb with the suspected fracture against the bird's body. Do not allow the bird to flap or kick a broken limb and make any injuries worse.
4. Examine the whole bird to look for other serious problems to take into consideration when deciding on a course of action. Does the bird have too many problems? Three major problems is a good rule of thumb to merit euthanasia. Remember that emaciation by itself counts as a major problem. The reason the bird is emaciated counts as another. For example, a bird may recover from two broken bones or one large laceration and one broken bone just fine, but an emaciated bird with a broken bone will often die. Species is also an important thing to consider, as temperament and housing needs affect what fractures are fixable and what methods are most appropriate.
5. Once you have identified a splintable fracture (see list of prognoses below), do not manipulate the limb further. If you suspect a fracture but are unsure, treat it as if it is broken and splint it anyway since it may be a greenstick or capillary fracture. Comminuted (smashed) or multiple fractures hold a poorer prognosis and will likely lead to a very large

callus or non-union. However, if the fragments are well-aligned, healing is possible. When in doubt, splint it and wait to see how it heals, or splint it and consult with your vet to get an x-ray and see how bad it is.

6. Palpate all areas of the body looking for painful, warm or swollen areas. Feel each bone individually by placing the thumb and forefinger of one hand on the joint at one end of a long bone, and the thumb and forefinger of your other hand on the joint at the other end of the bone. GENTLY apply tension to flex the bone. Each bone should feel firm and no movement should be detected. If abnormal movement is felt, carefully try to feel how severely the bone is out of its normal position, how many pieces you think it is in, and how close to the joint the affected area is. Don't forget to feel the keel and clavicles.
7. Minimize handling when possible by examining the entire right side before shifting your grip to examine the other side. Also try to keep the bird upright as much as possible. Do not turn birds with respiratory issues onto their backs.
8. If you have access to x-rays, it may be best with some birds to anesthetize them to prevent struggling during x-rays. Dog/cat veterinary practices may be unfamiliar with the needs of broken wild birds and since fractures in dogs and cats are not considered life-threatening, technicians taking x-rays may underestimate the risks of allowing birds to struggle during positioning for x-rays. Due to the likelihood of struggle leading to further damage to broken limbs, x-rays should be taken only after the fracture has been restrained unless the person taking the image is an expert bird handler. This also will show how well aligned the fracture is inside the splint. Since wild birds need to recover full function in their broken limbs, do not do anything to make the fracture worse! Remember that the soft tissues around the bone are vitally important and keeping the vessels, nerves and tendons functional can make all the difference for a successful outcome. Sharp broken bone ends can injure or sever these important structures. Soft tissue damage can be a death sentence. But if you do not have access to x-rays, you can still do a great job identifying and splinting fractures.

### Before beginning the splint

1. Keep splinting materials ready in a kit such as different weights of paperboard (such as Kleenex box), telfa pads, cotton balls, various thicknesses of foam packaging such as take-out food trays, thin wooden coffee stir sticks, Vetrap, and ribbon or paper tape; Micropore paper tape is ideal. Avoid scotch, adhesive, or masking tapes unless you really have no other options. The glue may soften with the heat of the bird's body (or time) and may result in a gummy mess on the feathers. These tapes also tend to pull out a lot of feathers when being removed. DO NOT USE WOVEN GAUZE as padding unless your splint will be completely encased in tape. Many birds will quickly pull it out one string at a time until the padding has been destroyed and your splint becomes too loose.
2. Find the scissors and a pencil or pen before you start.
3. Weigh the bird before splinting so you will have an accurate weight to determine dosage for medication if necessary.
4. If it is a compound/open fracture, you will also need wound cleaning and treating supplies such as gauze, cotton swabs, fine tweezers, dressings such as hydrogel or Tegaderm and disinfectant such as Betadine.

5. Always use padding on splints and over wounds. There must always be padding between any wood or cardboard products and the **bird's** skin or the bird will end up with serious skin lacerations or abrasions. Even flimsy-seeming Kleenex box can cut like a knife.
6. Once again, restrain only what is necessary to give support. Allow the bird to move and exercise uninjured limbs and joints.
7. **WHILE APPLYING THE SPLINT, WATCH FOR SIGNS OF STRESS.** Return bird to small, warm, covered housing IMMEDIATELY if signs of stress develop. (Heavy breathing, gasping, etc.) Allow the bird to calm before continuing.

#### Compound/open fracture

1. Pluck feathers with tweezers from the immediate area of the wound only. Pull feathers with the growth direction, except as necessary to not tear the tissue. Remove only the minimum necessary for the procedure: a 1/8 inch margin is usually adequate. Do not remove flight feathers, as permanent follicle damage is possible. It is better to let the soft tissues heal with the feather still in its follicle. You can always pull damaged feathers after the soft tissues have healed.
2. Thoroughly flush the wound with disinfectant such as dilute Betadine or Nolvasan, removing all foreign material, including feather debris. Clean and disinfect from the center of the wound towards the outer edges. Tissue glue such as Nexaband or sutures and dressings such as Hydrogel or Tegaderm may be needed.
3. Be careful to not flex the fracture area during cleaning—provide a temporary support to the side of the limb you are not working on if necessary to minimize movement during wound cleaning.
4. Apply the splint appropriate for the bone in question (see following pages). Dress the wound in such a way that it can be changed without removing the splint, if possible. This would dictate not using cardboard for the splinting material, since wet cardboard does not provide much support. Thin plastic such as from a yogurt container lid is a wet-able and lightweight possible support material (well-padded, of course), but provides poorer ventilation to the wound. Hexalite open-weave moldable splint may be another option but is too big for tiny birds. Songbirds heal fast enough that a hydrogel dressing under a splint often provides adequate wound treatment to allow for good skin healing while the fracture knits.
5. Oral antibiotics should be given to any bird with an open fracture.

#### After splint is on – watch carefully!

1. Do not tape entire limb, leave areas untaped to observe color, swelling, temperature - hot or cold, any of which could indicate a problem developing.
2. Re-do splint if swelling occurs. If the bird is extremely young, change the splint every 3-5 days to allow for growth. Usually birds that are old enough to be fully feathered do not require this with minimally-restrictive splints. Long bone growth occurs very early in small birds. Extremely young birds may heal fractures in less than a week.

3. Splints should remain in place for 7 days for most songbirds, medium-sized birds (such as pigeons) for 10 days, and larger birds for 3 weeks. The bigger the bone, the longer it takes to heal, leg bones allowed to bear weight heal faster than wing fractures. Remove the splint at the end of the appropriate time and examine the limb again, just as you did the first time, VERY GENTLY to see if there is any movement at the fracture site. You should feel the callus lump and it should be solid with no movement. If it is still wiggly, even slightly, re-splint and check again in another week. Figure 8 wing wraps on large birds should be removed every 2-3 days for wing extensions to prevent joint stiffness (stretch and hold repeatedly while supporting the fracture); this may require anesthesia in stressful birds. This is not usually a problem in songbirds or columbiforms in splints < 2 weeks.
4. When removing a splint with sharp pointed scissors, be very careful that you do not cut the bird's skin, especially when cutting up the backside of a tibiotarsus splint behind the knee. Similarly, when removing a shoe, be very aware of where the bird's toes are to avoid doing something unthinkable like snipping off a toe!
5. Non-unions should be euthanized.

### Prognoses of Typical Fractures

**Skull:** Birds with skull fractures may heal quite well as long as the bird is not displaying abnormal neurological signs (depression, lack of coordination, nystagmus, limbs held stiffly, etc). Make sure all caregivers are made aware of the bird's condition to avoid aggravating the injury during routine handling. Birds that become more abnormal neurologically with time in care should be euthanized.

**Beaks:** breaks to the beak are splintable if located mid-shaft on the mandible or maxilla. Bear in mind that wild birds MUST have good beak alignment (unless you are treating a crossbill or skimmer!) since they cannot get a beak trim once a month for the rest of their lives. Misaligned beak tips are grounds for euthanasia, since overgrowth will occur and the bird is likely to eventually starve to death due to being unable to eat. Dislocations of the jaw may require placement of an esophageal feeding tube while the mouth is healing, so consult your veterinarian for feasibility. This is not routinely done for songbirds, but is common for waterfowl. Taping the beak shut at night and un-taping during the day during feedings is a possibility but is very labor-intensive and stressful for the bird. Be careful to not tape over the nares and obstruct breathing. For hummingbirds, taping can be successful since they do not need to open their mouths very far to get their tongues out to drink.

**Spine:** Fractures of the back have a vanishingly small chance of recovery and euthanasia is recommended. Breaks to the caudal spine may result in a limp tail. Birds cannot be released without control of their tails since the tail is very important in flight. Spinal fractures are most commonly palpated as an abnormal angle at the cranial end of the synsacrum, mid-back. Birds with this fracture often display one (or both) limp legs, poor vent tone, or difficulty emptying the cloaca.

**Clavicle:** A simple metacarpal wrap to restrict flapping provides enough restraint to allow for clavicle healing. See instructions for where to apply tape. For a calm bird, it may only be necessary to tape the wing of the side that is broken. However, some songbirds can be quite stressed in captivity and will need to have both sides taped to adequately restrict movement.

Do not over-palpate the clavicles since you can easily un-align the bones by pressing on them. Gently run your finger along the bones and also puff the feathers out of the way to visualize the area. Bruising at the top of the keel is a big hint to look for this type of fracture. Impacts into windows and cars often break clavicles. Large birds such as pelicans may have clavicle fractures that seem incidental and do not require any sort of wrap. Diving birds recover well floating in pools with minimal handling.

**Coracoid:** The coracoid is a strong, strut-like bone that extends from the shoulder to the inside of the cranial end of the keel. It is seated on a ledge on the keel and provides the chest with the strong support needed for the flight muscles. The coracoid can be fractured along its length or dislodged from its ledge on the keel, typically by impacts to the chest. Because this bone is located beneath the breast muscles, in most cases it cannot be palpated during examination (except in some large birds), and any injuries can be quickly made much worse by trying. If such an injury is suspected, do not over-handle the shoulders or chest—you may inadvertently turn a healable injury into a euthanizable one, or even into a case of sudden death. The best way to diagnose this injury is seeing the tipped up wingtip, no flight ability, and sometimes a drooped shoulder. Large birds tend to display a general wing droop, but some waterfowl may hold the wing quite normally.

Although there is the possibility that a coracoid that is broken or dislodged from its ledge may press on the vessels of the heart and cause fatal hemorrhaging, this does not occur very often (and is the reason to not handle the bird very much). If the end of the coracoid is touching the keel at all, it can heal well with full flight, although flight that is less than perfect may be inadequate for long distance migrators or aerial insectivores. The best treatment is to confine the bird to small caging to restrict movement for 10 days (songbirds) to 3 weeks (larger birds), and keep handling to a minimum. Give the bird as stress-free an environment as possible and a feast of appropriate food items to encourage self-feeding. Restraining the wings has not been shown to improve the healing process, although certain stressy birds can be kept from excessive flapping by the application of metacarpal wraps. Flight test the bird after the confinement period; most will fly well on the first outing and are ready for the aviary. A few will show no flight ability and should be euthanized. Those with any ability to maintain or gain elevation should be given more time to heal and then be re-flight-tested.

**Keel:** Keel fractures are common with car and window-hit birds. Always remember to examine the keel; birds are often presented for not being able to fly but have no wing injuries, and keel injuries are easily missed. The likelihood of recovering full flight is excellent. Keep your eye out for severe pectoral muscle damage under bruised skin. If the breast muscle feels lumpy or watery, consult your veterinarian, as the injury may heal faster if it is opened and flushed or debrided. Extensive breast muscle damage can heal quite well with proper wound management.

**Joints:** Birds with joint fractures usually heal with the joint frozen, and should be euthanized. How close to the joint is “too close” is a judgment call and is somewhat proportional to the size of the bone, but the author usually chooses euthanasia for fractures closer than 1/8-3/16 inch (3-5mm) in most songbirds. Tarsometatarsus fractures can be okay a bit closer to joints than those on other bones. As long as the bird can do what it needs to do with the foot when healed, toe joint fractures are relatively inconsequential.



**Femur and humerus:** Typically require surgical pinning. Consult your veterinarian if you have a patient that is a good candidate for surgical repair (minimal or no additional problems, alert, good body weight). If surgery is not an option, and the fracture is not displaced from its normal position, taping the limb to the body is feasible but holds a poor prognosis—non-union is highly likely, especially in the case of humerus fractures, although some rehabilitators have reported good results with a body wrap. If possible, after taping a wing to the body for a humerus fracture, get an x-ray to check on the alignment of the bone fragments. If the bone ends are not in line and touching, euthanasia is recommended if pinning is not an option. Taping the femur is more feasible for a nestling or fledgling-aged bird, since hand-feeding is routine and they will not be not stressed by sitting in a nest for a week. Adult birds may require force feeding which is often quite stressful, although some birds will eat if food is presented in an easily-accessible manner. This also gives them something to do while they are laid up.

**Radius/ulna:** If just one of these bones is broken, the unbroken one acts as a splint for the other and some veterinarians do not believe additional support is needed. The author, however, prefers to use a flat support for under the wing and feels that the alignment of the broken ends is better when supported, especially if the ulna is the broken bone. If both bones are broken in line across the wing, there is usually severe soft tissue injury, and the bird has a poor prognosis. If the two bones are broken offset from one another, the wing may heal just fine with splinting. Sometimes what is called a *synostosis* is formed where the callus grabs onto the other bone and forms a solid bridge between the radius and ulna. This results in an inability to extend the wing because these bones must be able to move in relation to each other. These cases should be euthanized (unless you have a avian orthopedic surgeon willing to expend effort on poor prognosis cases).

**Wingtip/metacarpals:** This area is difficult to palpate on small birds. Non-union is common with compound fractures here, but simple fractures often heal well. If the wingtip is swollen and bruised, a fracture is likely. Splint it if you are unsure. There are two joints past the wrist—fractures and luxations of these joints may not heal in a stable manner.

**Tibiotarsus:** This is one of the most common fractures and most challenging splints to apply to small birds, but can heal quite well even if the bird arrives with the leg dangling and rotating at the break. It may be helpful to have another person restrain larger songbirds (>100 grams-ish), but with small bodied birds, there just isn't room for more fingers in the way. Holding the bird against your body can help free up more of your fingers from restraint duty. A stockinette or even a mealworm bag with a hole for the injured leg to poke out of sometimes can help with restraint if you are alone and the bird is wiggly. Be careful to not make the break worse while getting the leg out the hole. Alcohol can assist in getting feathers out of your way when taping the splint on, but don't get any on open wounds since it stings.

Compound fractures should have the exposed area cleaned with an antiseptic before applying the splint. If you are concerned that the telfa pad that lines your splint will not keep the exposed tissue moist enough, you may cover the wound with hydrogel or Tegaderm before applying the splint. The dressing will keep it moist for at least 48 hours before it dries out. Small bird wounds heal so quickly that this is long enough to do a lot of good. Applying the

splint should pull the bone to its proper length, and may result in the protruding fragment being pulled inside. If the bone end is dry and darkly colored, it is dead and the bird should be euthanized. Compound fractures of the tibiotarsus may heal with a very large callus that may necessitate lots of physical therapy for a full recovery, or the callus may cause the tendons of the back of the leg to deviate off the groove of the hock (a complication warranting euthanasia). Compound fractures in herons/egrets should be surgically pinned, as they tend to do poorly in splints. Tibiotarsus fractures that are very close to the knee heal best with surgical pinning but this is often not feasible for small or very young birds.

Birds with tibiotarsus splints may require a shoe to keep the foot in a normal position, but if you give the bird a while to get used to the splint you may find that the bird walks and perches fairly normally within 2-3 days of applying the splint. Be sure to keep the bird on soft materials if it is knuckling the foot to avoid injuries to the top of the toes.

Both legs CAN be splinted at the same time, but the bird will usually require a 'donut' shaped supportive substrate of rolled towel or other material to hold the bird comfortably upright. Many adult birds will sit in their donut and eat if food is within reach. Pigeons are especially amenable to this. Specially arranged food dishes, millet sprays within nibbling distance, etc. can cut down on the need to force feed, and also give the immobilized bird something to do.

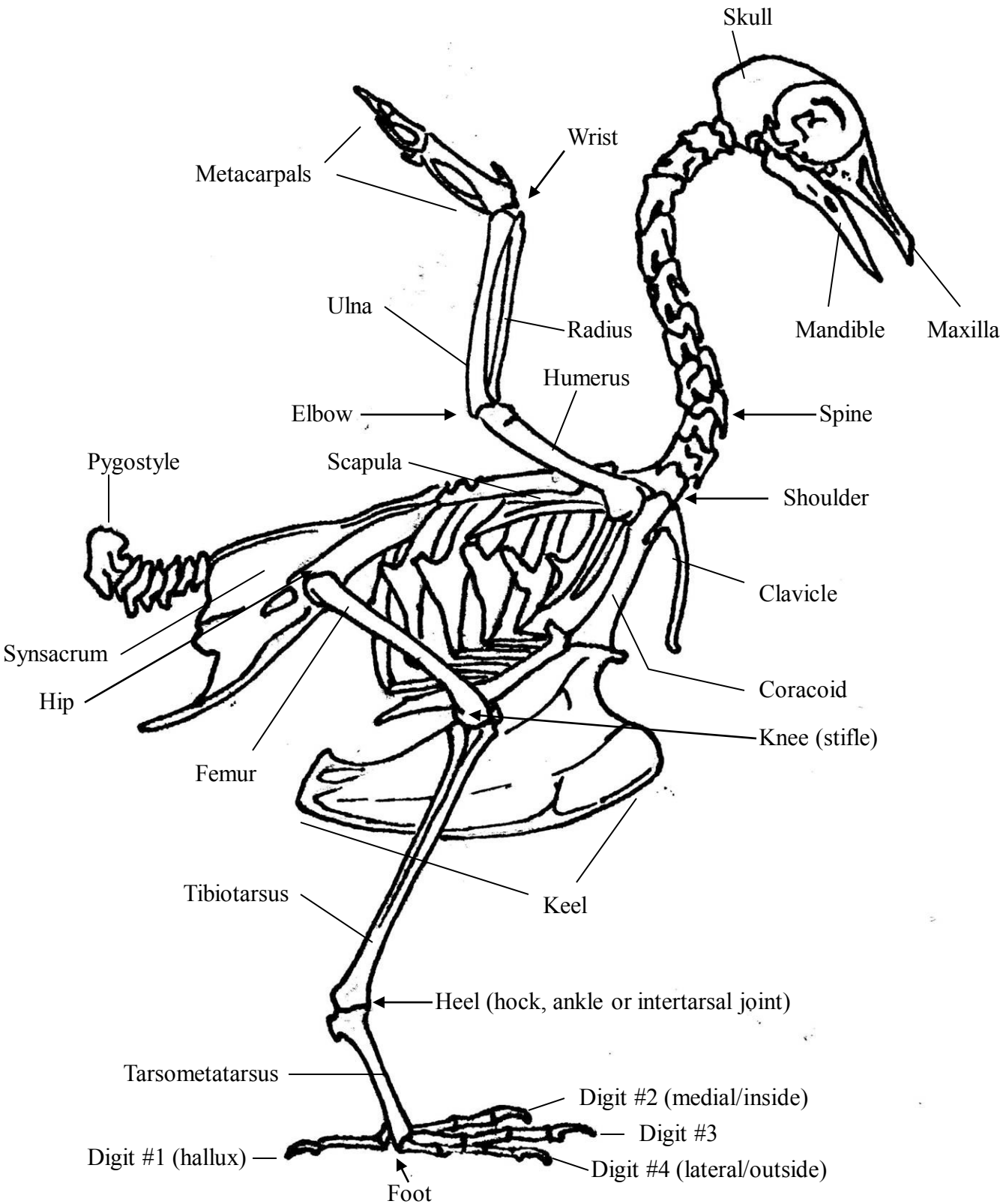
**Tarsometatarsus:** These fractures are easy to splint and heal very well in songbirds. Compound fractures here, though, are more prone to vessel and nerve damage and may result in the bird losing circulation to the foot. This is hard to predict, however, so it is usually worth splinting it anyway and seeing how it heals. If the foot becomes dark and appears to be drying out, euthanasia is recommended. In herons, egrets, and larger waterfowl these fractures heal best with surgical pinning as it is difficult to get a splint snug enough to stabilize the leg without having a tourniquet effect and causing the foot to swell. Mallards do well with a waterproof walking splint.

**Foot:** See Joint Fractures section above. Feet with restricted flexibility are more functional in ground birds than in birds that perch. If the fracture is not open, it often is worth splinting the bird and waiting until it has healed to see what the bird can do with the foot in relation to what it needs to do. Open fractures of the foot are often extremely contaminated or have exposed necrotic bone and generally indicate euthanasia.

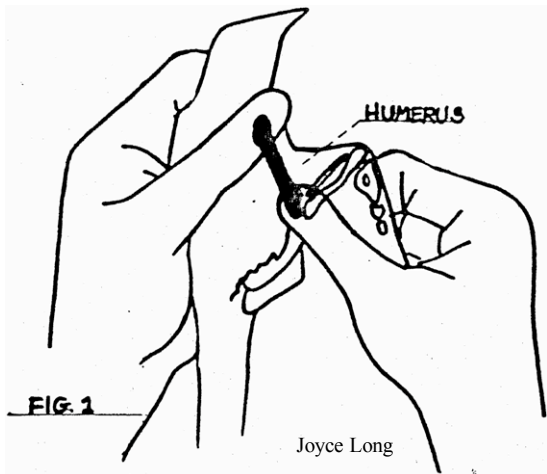
**Toes:** Toe fractures heal well, and if they do not, amputation is a viable possibility. It is preferable to amputate a toe rather than to allow it to permanently fold under the rest of the foot, as folded-under toes will result in long term pain for the bird. Songbirds need to be able to perch with the foot. Removal of both halluxes typically results in a songbird that cannot perch strongly enough to be released. Raptors are considered okay to lose the outer toe (#4) but really need the other three, especially the hallux (#1). It is debatable whether or not a raptor with only two toes (#1 plus #2 or #3) will be able to hunt well enough. If the other foot is uninjured and the bird has no other disabilities, this may be adequate. Similar issues arise with web-footed birds, as loss of a toe and its webbing can substantially affect swimming ability.

Check USFWS guidelines for legality of any amputations to migratory birds.

# The Avian Skeleton



# EXAMINING THE WING FOR POSSIBLE FRACTURES

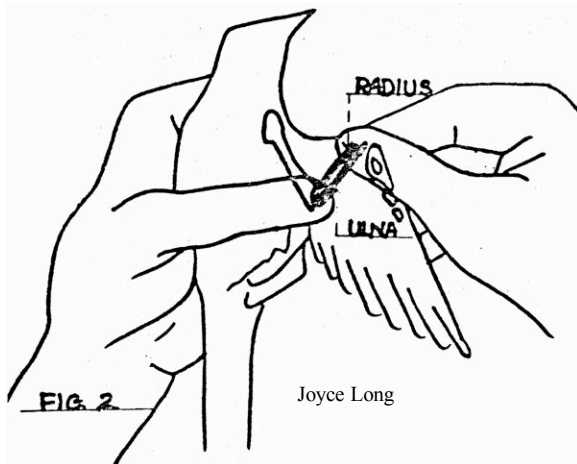


Each bone or section of wing should be examined individually. The examination must be very GENTLE, as rough handling can cause fractures, or make existing ones worse. Do not examine for fractures if the bird is stressed, or becomes stressed during the examination. Allow the bird to become warm and calm before handling.

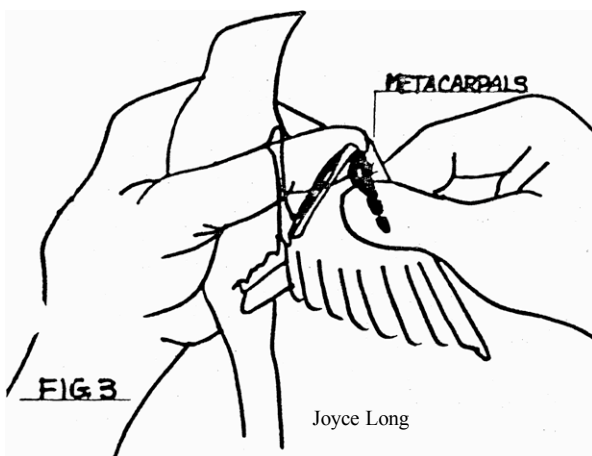
In FIG. 1 each end of the HUMERUS is held firmly, the shoulder underneath the left thumb, and the elbow between the right thumb and forefinger. Then GENTLE tension is applied to the rest of the bone. Any movement, where the bone should be solid, indicates a fracture.

If the bird has a HUMERUS fracture, follow the directions for radius/ulna figure 8 wrap but there is no need for the splint. Steps 6-7 must be followed to bind the wing to the body.

Beware lifting the wing of doves to examine the under-wing area—their flight muscles are so strong and adults can be so stressed that they snap their humerus during handling.



In FIG. 2 the RADIUS & ULNA are examined together. The elbow is held between the left thumb and forefinger, and the wrist between the right thumb and forefinger. In very small birds it is difficult to tell if the fracture is in one bone only, or in both the RADIUS & ULNA. But, in larger birds it is possible to determine this with practice. Attempt to identify which bone is broken and how many pieces it is in.



In FIG. 3 the larger METACARPAL bone is the only one that can be manipulated well in the wing tip area. However, it may be fractured and can be GENTLY held at both ends, and tension applied to its middle to check for any movement (fracture). Bear in mind that some movement at the various small bone joints of the wingtip is normal. Compare to the bird's other wing if necessary. It is normal for some species to have very floppy-feeling wrists, especially in young birds.

# SPLINTING FRACTURES OF THE WING

## Figure 8 wrap for humerus or radius/ulna fractures with support

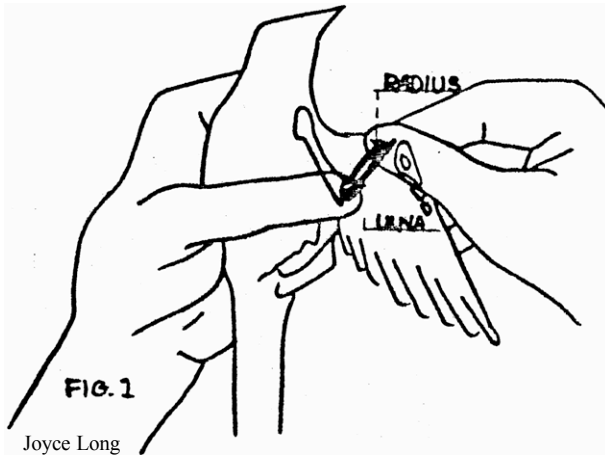


FIG.1 The RADIUS & ULNA are examined together. The elbow is held between the left thumb and forefinger. In very small birds it is difficult to tell if the fracture is in one bone only or in both the RADIUS & ULNA.

Use Micropore paper tape for small birds (they will slip out of Vetrap), Vetrap for larger birds. Width of tape or Vetrap should be about  $\frac{1}{2}$  as wide as elbow-wrist distance. Tape can be applied in several short sections that become attached end to end.

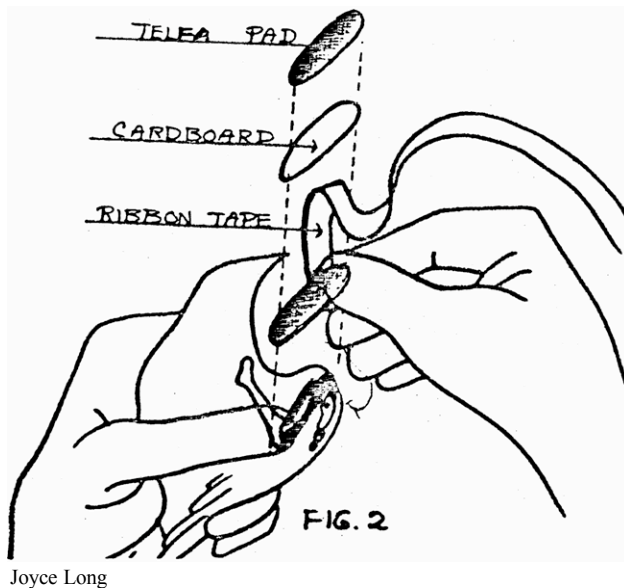


FIG. 2 Using the unfractured RADIUS & ULNA in the opposite wing as a model, draw and cut out a cardboard splint that will reach & include both of the joints at either end of the fractured bone. (if it is too short, it will shift out of position & not provide the support necessary. If too long or too wide it may poke or cut into the bird.) Pad the cardboard with a piece of TELFA PAD cut in the same shape as the cardboard. Make the telfa pad a bit larger all around than the support, especially to cushion the armpit area. Use a small amount of gluestick to attach the telfa pad to the cardboard. Apply a piece of tape to the upper edge of the splint on the side that will be closest to the bird's body. (See the diagram.) The finished splint is applied to the underside of the wing, supporting the RADIUS & ULNA.

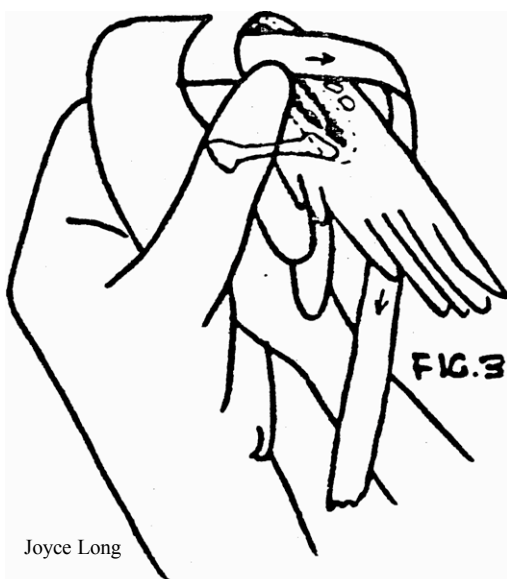
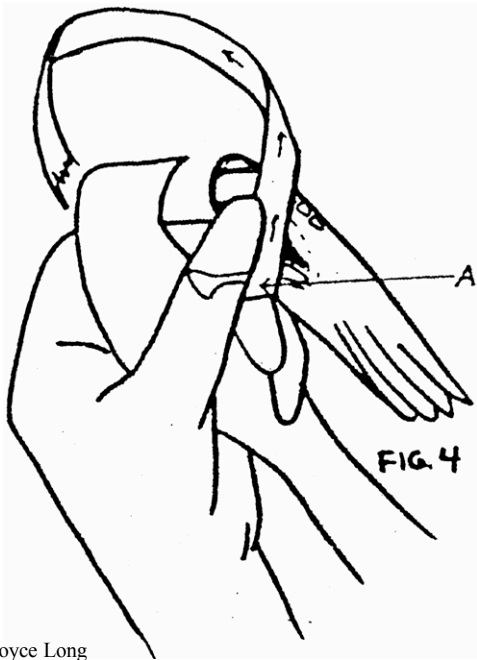


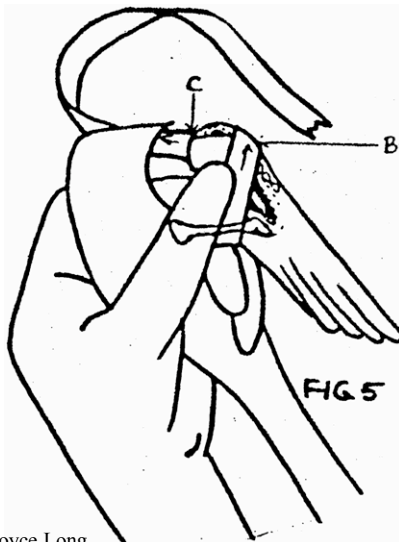
FIG. 3 With the splint under the RADIUS & ULNA, with the wing in a normal folded position, bring tape over the top of the wrist joint and then under the outer edge of the wing and toward the body.

# SPLINTING FRACTURES OF THE WING CONTINUED



Joyce Long

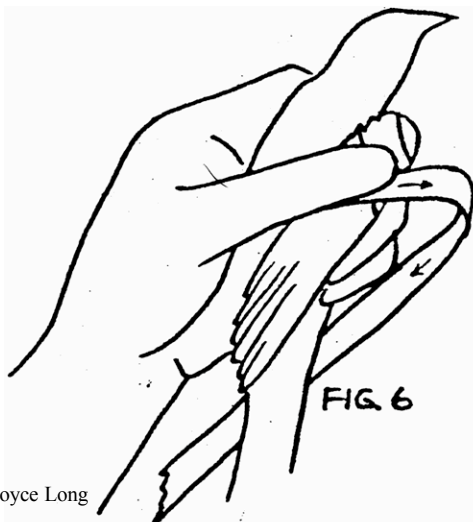
FIG. 4 Tape or Vetrap must come up behind & around the elbow joint (A) or it will slip off!!!



Joyce Long

FIG. 5 Wrap around outside of the wing (B) and back around behind the wrist joint again (C). Repeat steps 3 & 4, (above) which will result in doubling the wrap layer around the wing. Large muscular birds such as geese and gulls need very secure wraps, more restrictive than those for songbirds, and will need extra layers of wrap to keep them from being able to extend the elbow. They are also more prone to joint stiffness from restricted movement.

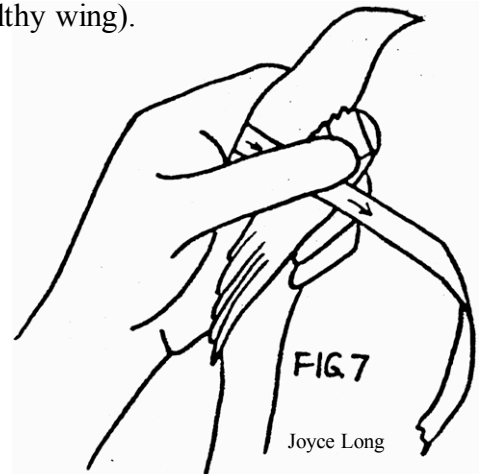
NOTE: If the splint is well-secured around the elbow, there is no need to bind the wing to the body for radius/ulna or metacarpal fractures. Adult birds may become depressed and stop eating when body wrapped. Only wrap the wing to the body if necessary to keep the bird from getting its elbow loose or if it is a humerus fracture. If necessary, follow FIG. 6 and 7 instructions.



Joyce Long

FIG. 6 After step 4, place the wing in a natural, comfortable, folded position & wrap the tape across the keel (not the crop) & under/behind the opposite wing, leaving the healthy wing free. If the wing is droopy, run the tape around the body the other way i.e. over the back and under the other wing in order to lift the wing dorsally a little.

FIG. 7 Stop after tape has gone around bird once & before crossing wing with tape to make sure the wing is in a natural position matching the healthy wing. Then tape across wing & around bird again, applying tape on top of the 1st layer. Bird will be encircled with tape twice (except for healthy wing).

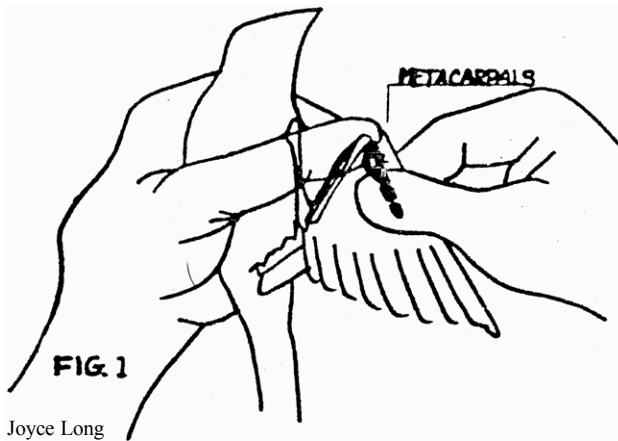


Joyce Long

The wrap should be firm, but not tight enough to interfere with breathing. The tape is too loose & will come off if you can fit a finger underneath it. Leave a tape tab of about 1/8 inch so the end of the tape will be easily found when the splint is to be removed.

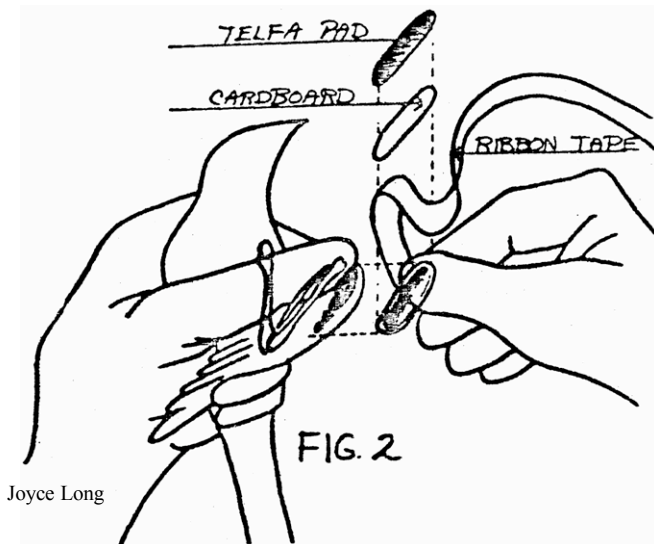
# SPLINTING FRACTURES OF THE WING

## Figure 8 wrap for metacarpal fractures with support



Joyce Long

FIG. 1 The larger METACARPAL bone is the only one that can be manipulated well in the wing tip area. However, it frequently is fractured and can be GENTLY held at both ends, and tension applied to its middle, to check for any movement (fracture).



Joyce Long

FIG. 2 Using the unfractured METACARPAL in the opposite wing as a model, draw and cut out a cardboard splint that will reach & include both of the joints at either end of the fractured bone. (if it is too short, it will shift out of position & not provide the support necessary. If too long or too wide it may poke or cut into the bird.) Pad the cardboard with a piece of TELFA PAD cut in the same shape as the cardboard. Apply a piece of TAPE to the upper edge of the splint on the side that will be closest to the bird's body (see the diagram.) The finished splint is applied to the underside of the wing, supporting the METACARPAL.



Joyce Long

FIG. 3 With splint under the METACARPAL bring tape over the top of the wrist joint and then under the outer edge of the wing and toward the body.

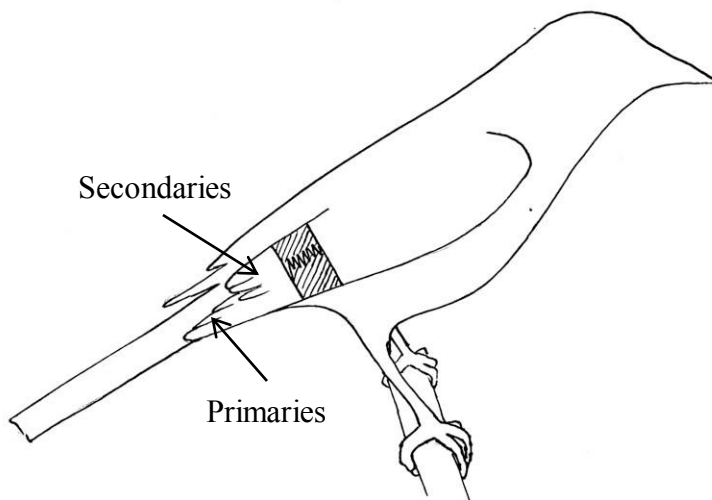
Finish figure 8 wrap per instructions on page 12 FIGS. 4-5.

# METACARPAL WRAP

This wrap may be useful for droopy wings that do not have an obvious cause for drooping at the wrist: for example, a bird that has no obvious fractures but has wing feathers touching the ground. Also useful for clavicle and coracoid fractures to prevent flapping while allowing enough movement to keep joints from becoming stiff. Use your best judgment to decide whether to apply to one wing or to both in those cases. If the wing is drooping at the elbow or shoulder, use a slit-wing wrap (next) to raise the joint into a normal position.

Some rehabbers use this wrap for radius fractures when the ulna is uninjured. It also may be useful for birds that have had sutures to the shoulder or wing, where flapping may cause the sutures to rip loose.

This wrap CANNOT work if the bird is missing its secondary feathers! Don't forget to pay attention to where feathers may be missing.



Fold the wing into a normal position against the body. Apply Micropore paper tape (or other non-sticky residue generating tape) across the primary and secondary feathers NEATLY as shown. If you do a good job, the wing tip of the wrapped wing will closely match that of the uninjured wing. Apply at least two layers of tape and pinch it snug against the feathers. If the bird wiggles out of the wrap, apply it again higher up the feather shafts and use a wider piece of tape.

## SUPPLEMENTATION FOR FRACTURED BIRDS

Birds on diets with calcium:phosphorus ratios of at least 2:1 should not need supplementation. The author supplements adult birds or juveniles not on well-balanced diets (e.g. carnivores, piscivores) as follows:

Adults: 150 mg/kg elemental calcium orally once daily x 7-14 days

Growing chicks: 150 mg/kg elemental calcium orally twice daily x 7 days (songbirds), x 14 days (larger chicks), or until fracture is stable.

### Calcium slurry recipe (100 mg/ml):

- 5 grams calcium carbonate powder (2000 mg elemental calcium) (available at [www.lef.org](http://www.lef.org))
- 10 ml Ora-Plus suspension vehicle (available at Amazon.com)
- 10 ml water

This is very easy to make, yields a higher concentration calcium supplement than calcium glubionate (23 mg/ml) so less volume must be given, and does not contain sweetener.



# SLIT-WING WRAP

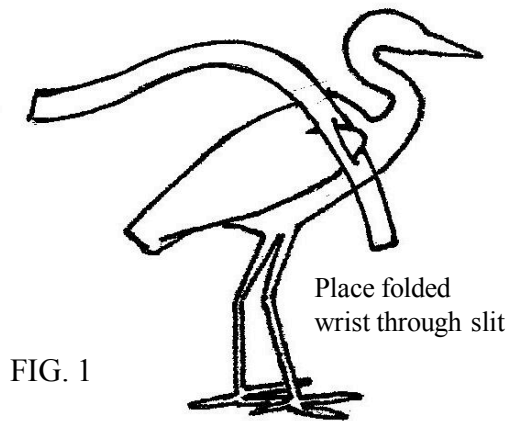


FIG. 1

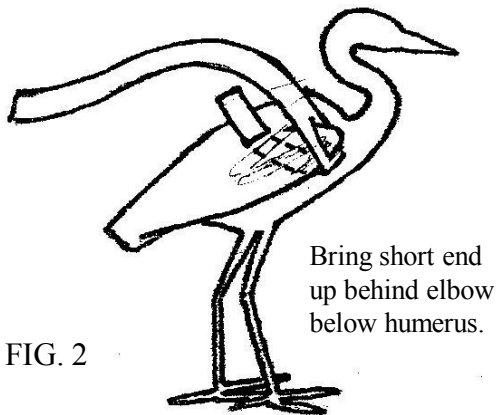


FIG. 2

Fold the wing into a normal position. With the short end away from the bird and the long end over its back, slip the bird's wrist through the slit, snugging it down as far as you can, as shown in FIG 1. Fold the short end under the wing and bring it up behind the elbow as shown in FIG 2. Stick the Vetrap short end to the underside of the long end as shown in FIG 3. Flatten the pieces together firmly.

Now use the "handle" you have just created on the wrist to move the wing into as normal a position as you can. Wrap the long end over the bird's back, behind the opposite wing under the elbow, across the keel, and in front of the legs as shown in FIG 4. Do any last position adjustments and pass the Vetrap across the droopy wing again and you should finish with the Vetrap end over the bird's back. Tab the end and apply a piece of tape to secure. Remove wrap weekly to check progress. Be sure to not make the wrap too tight.

This wrap is excellent for providing support to an unfractured but droopy wing that is drooping at the elbow, dragging on the ground. It raises the wrist into a normal position, and is especially effective for shorebirds and other waterbirds. Songbirds will often slip out of this one, but I have had excellent results with avocets and pelicans.

Cut a piece of Vetrap that is long enough to go around the bird twice. It should be cut to a width half the bird's elbow-wrist distance. Cut a longitudinal slit in the Vetrap slightly larger than half as wide as the bird's wrist area. Place the slit as far from one end of the Vetrap as the wing is wide when folded.

Stick short end to underside of long end, use to lift wing into correct position.

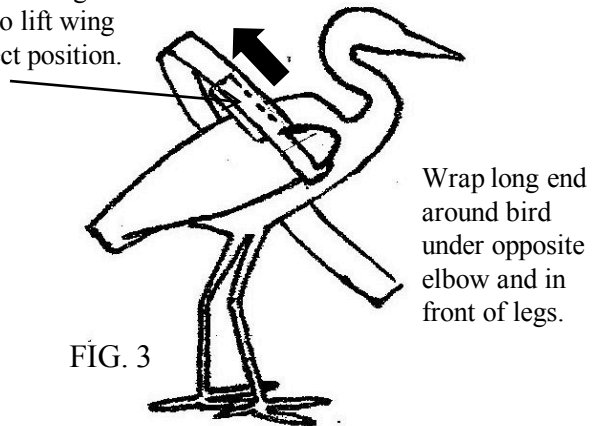


FIG. 3

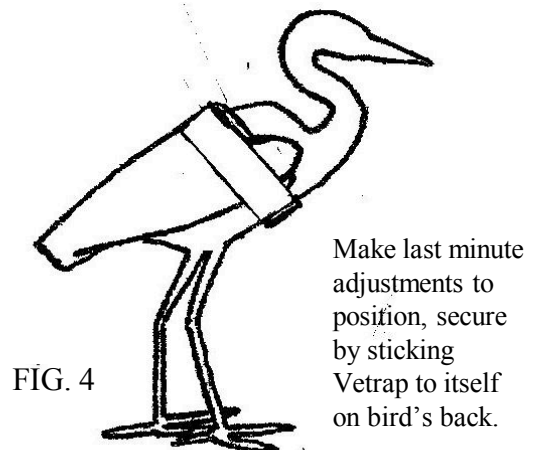
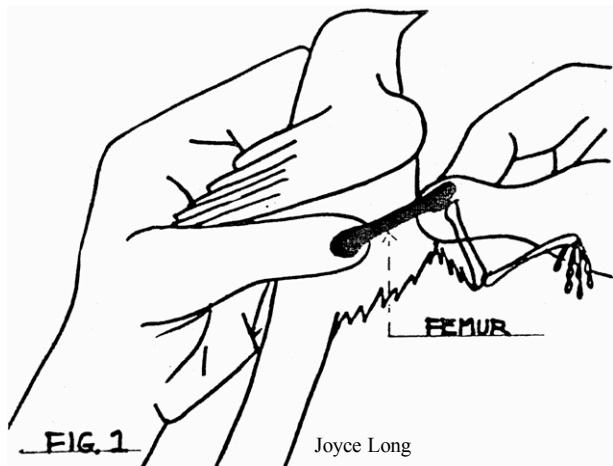


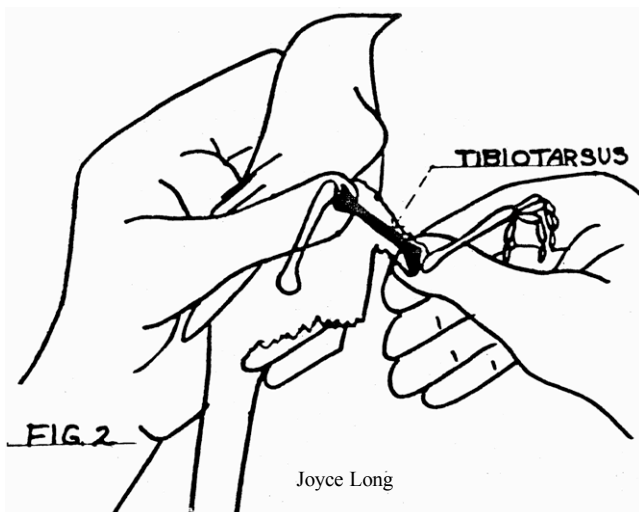
FIG. 4

# EXAMINING THE LEG FOR POSSIBLE FRACTURES

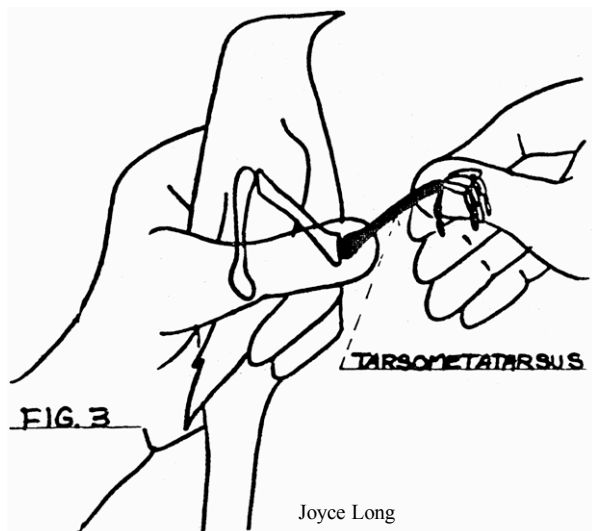


Each bone or section of leg should be examined individually. The examination must be very GENTLE, as rough handling can cause fractures, or make existing ones worse. Do not examine for fractures if the bird is stressed, or becomes stressed during the examination. Allow the bird to become warm and calm before handling.

In FIG. 1 the left thumb is placed at the head of the FEMUR at the hip joint. The knee is pulled out slightly and held between the thumb and forefinger of the right hand. Each end of the FEMUR is thus held firmly and GENTLE tension can be applied to the rest of the bone. Any movement, where the bone should be solid, indicates a fracture.



In FIG. 2 the knee is held between the left thumb and forefinger and the ankle between the right thumb and forefinger. GENTLE tension can then be applied to the TIBIOTALARSUS to determine if it is fractured.

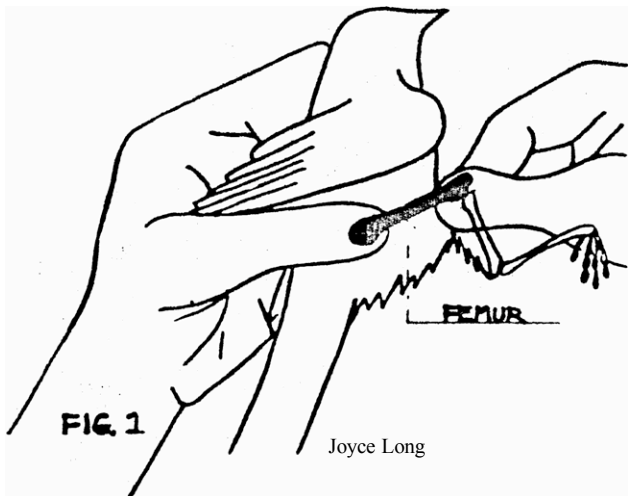


In FIG. 3 the ankle is held between the left thumb and forefinger and the foot between the right thumb and forefinger. GENTLE tension can then be applied to the TARSOMETATARSUS to determine if it is fractured.

Examine the foot and each toe carefully to determine if there are fractures or luxations. If the bird can stand, make sure part of the exam includes close observation of each toe for abnormalities.

# SPLINTING THE FEMUR

To immobilize prior to surgery or as the only treatment



This wrap works well for songbirds, less well for other groups of birds. In general it works well for species where the length of the tibiotarsus is similar to the femur—if the tibiotarsus is a lot longer than the femur, the wrap requires substantial modifications since the bones do not ‘stack neatly’ when folded.

FIG. 1 The left thumb is placed at the head of the FEMUR. The knee is pulled out slightly and held between the thumb and forefinger of the right hand. Each end of the FEMUR is thus held firmly and GENTLE tension can be applied to the rest of the bone. Any movement, where the bone should be solid, indicates a fracture.

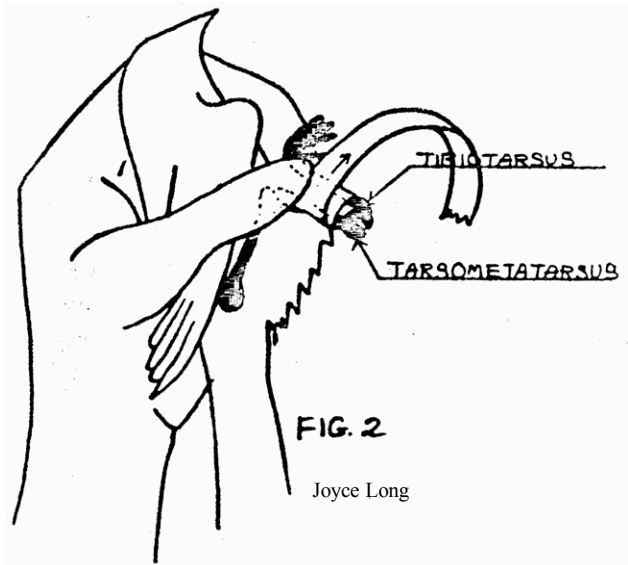


FIG. 2 In order to splint the FEMUR the remainder of the leg must be immobilized first. Use tape wrapped twice around the TIBIOTARSUS and the TARSOMETATARSUS as in the diagram.

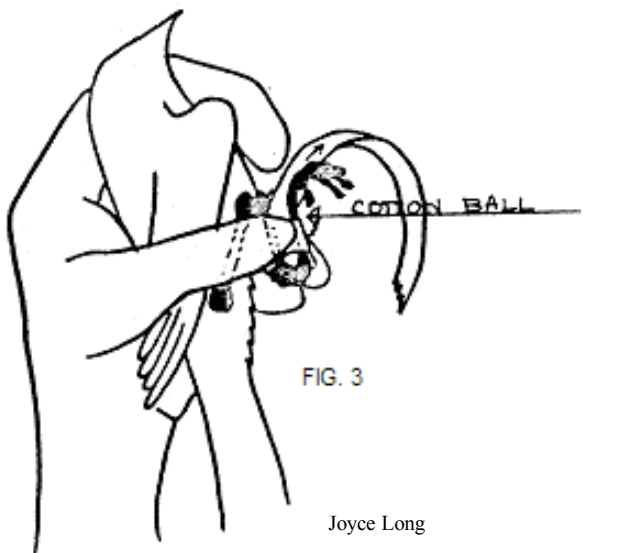


FIG. 3 A cotton ball (or part of one, or large wad of them, depending on the size of the bird) is taped on the inner side of the leg. Start by bringing the tape between the knee & the foot & then down over the cotton. Wrap the tape around several times to secure the cotton well. Be sure it does not block the vent or slip to do so as time passes.

## SPLINTING THE FEMUR CONTINUED

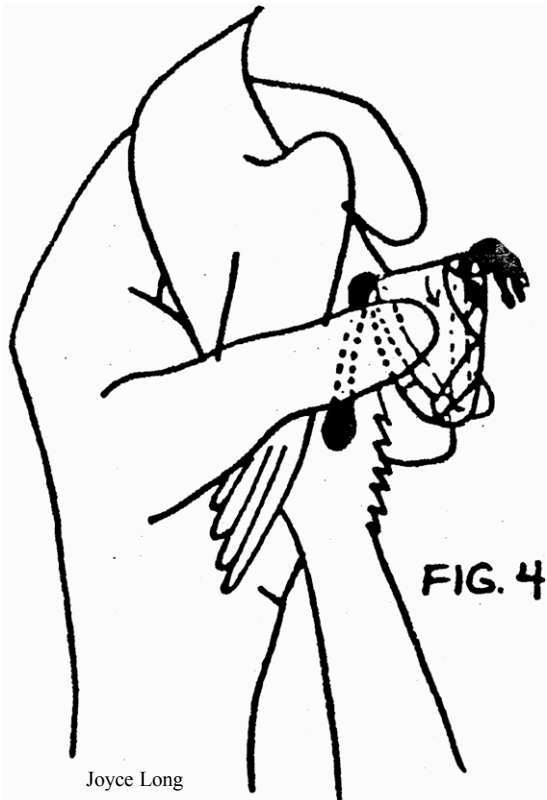


FIG. 4 Make a triangle shape as in the diagram, padded on the abdomen side with cotton. The purpose of this pad is to keep the leg in a normal position parallel to the other leg, rather than being folded inward against the abdomen. The femur shape will be distorted when it heals if this happens.

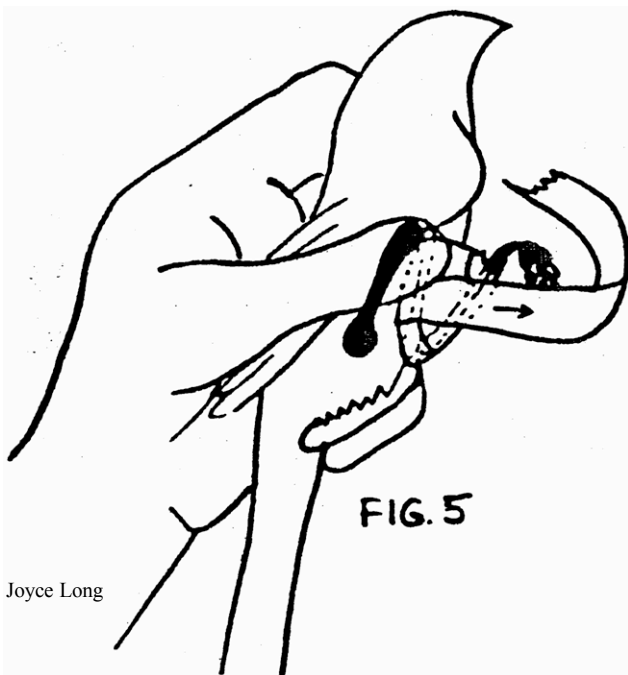


FIG. 5 Place the triangle next to the body with the FEMUR as straight as possible. Wrap tape at least twice around the bird, securing the leg in place. Again, make sure the vent is not blocked. Leave a tape tab of about 1/8 inch so the end of the tape will be easily found when the splint is to be removed.

It is helpful to run the tape across the bottom of the foot to hold digit #1 back and prevent it folding forward with the other toes. This also ensures the foot's plantar surface is oriented in the correct direction.

# TIBIOTARSUS: MAKING THE SPLINT

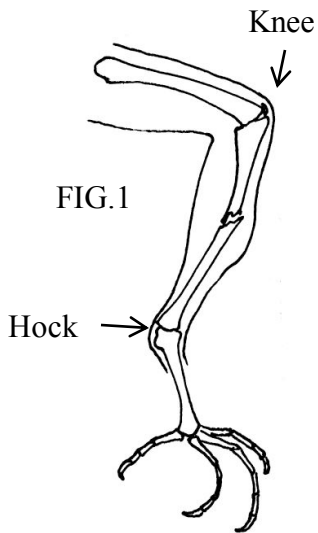
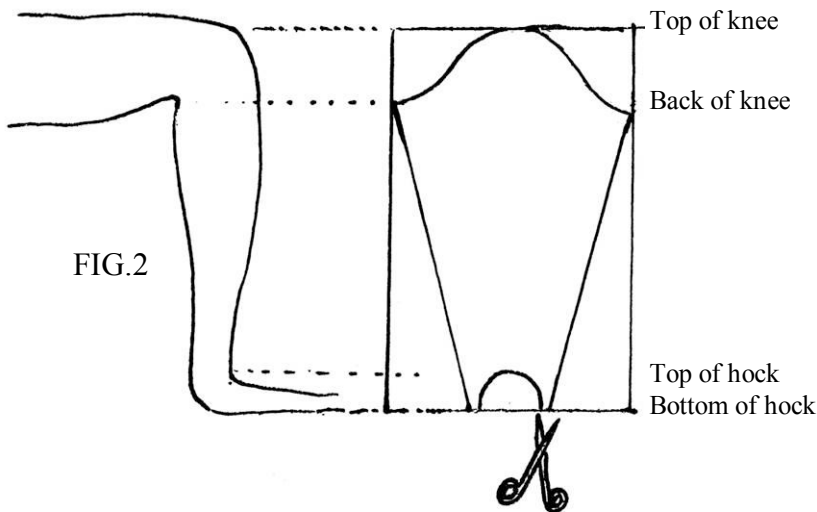


FIG. 1 The knee is held between the left thumb and forefinger and the hock between the right thumb and forefinger. GENTLE tension can then be applied to the TIBIOTARSUS to determine if it is fractured. This is the most common fracture in chicks.

FIG. 2 Using the unfractured TIBIOTARSUS in the opposite leg as a model, measure the length from the top of the knee to the bottom of the heel (see drawing below) with the leg folded into a 'Z' shape. The splint must reach to & include the joints at either end of the fractured bone, although it does not immobilize either. If it is too short it will shift out of position & not provide the support necessary. If it is too long, it may poke or cut into the bird. As in the diagram, cut away the parts marked in order to make the splint conform to the shape of the leg. The final splint is a tapered cone shape, reminiscent of a hockey shin guard.



Make the splint out of lightweight bendable material. For songbirds, Kleenex box works well. For larger birds, this material will also work, but you may wish to tape a piece of wood (for example: coffee stir stick) lengthwise on the outside of the splint along the lateral edge to provide extra strength. Thermoplastic moldable splint or Hexalite moldable plastic mesh or even SamSplint are possible materials for larger bird splints, but any sharp or poking parts must be well padded or it may cut the bird.

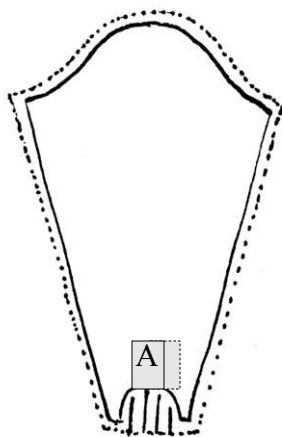


FIG. 3 Pad the splint with TELFA cut into the same shape but slightly larger than the cardboard. This will pad the skin from the cardboard edges. To pad the top of the tarsometatarsus, cut strips into the telfa pad at the semi-circular area. Also add a rectangle of telfa that wraps across the top of the curve at the splint bottom (A)

FIG.3

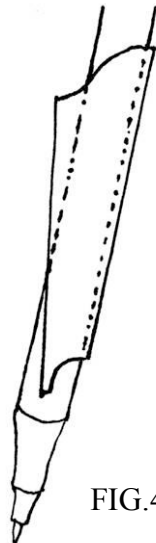


FIG.4 Carefully bend the paperboard around a tubular object that is close to the size of the leg, such as a pen or syringe. Do not allow the cardboard to crimp, rather bend it to have a smooth curve. Make sure the center of the top and bottom curves are in line with each other. Attach the telfa pad with a small amount of gluestick.

FIG.4

## TIBIOTARSUS: APPLYING THE SPLINT

Applying this splint can be quite challenging, even for the experienced rehabber. Be sure to have many strips of tape ready and waiting for when you put the splint on.

Restrain the bird so that you have access to the leg. If the bird is small, hold it against your body and extend the leg by the knee, supporting the broken segment as best you can. If feathers are in the way, you can use an alcohol pad to wet them down, bear in mind alcohol stings on open wounds. Slot the leg into the splint as shown in FIG.6 and grip the leg firmly through the splint at the break. This gives you a secure grip supporting the fracture while you apply the first piece of tape.

Once you have a piece of tape holding the splint on the leg, flex the tarsometatarsus and seat it into the curve at the bottom of the splint, making sure the strips of telfa pad are padding the curve of the cardboard at A. Seating this segment of leg into the curve also serves to reduce the fracture and pull the bone fragments into proper alignment. Apply a “stirrup” (B in FIG.7) of tape from the splint around the bottom of the heel to hold the leg in a semi-flexed position. This keeps the splint from sliding down the leg.

Tape all areas of the splint snugly, paying especial attention to the back of the knee. Failure to adequately tape here can allow the knee to move closer to the hock.

Most birds will begin to use their splinted leg more or less normally after a day or so. Be sure to monitor the foot for swelling or other signs of problems. If the splinted leg is held sticking away from the body it may be necessary to hobble the leg to restrict its movement.

Monitor location A for abrasions. Tape very securely behind the knee. This spot also needs to be monitored for abrasions every 1-2 days.

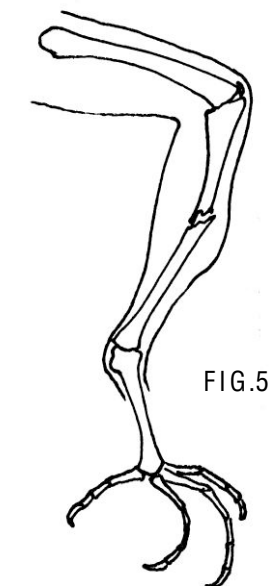


FIG.5

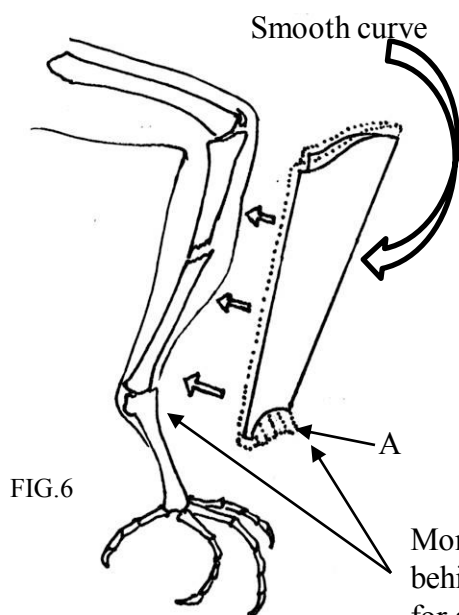


FIG.6

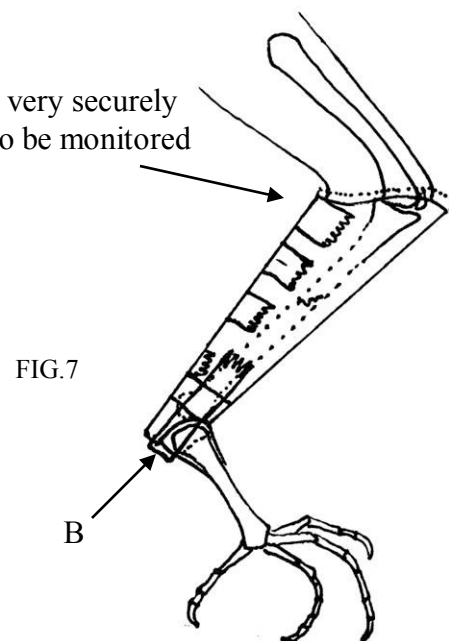


FIG.7

If the bird is a nestling, tissues can be arranged to let the splinted leg hang down into a depression in the nest. Adding padding to the bottom of the basket and perches can make any injured bird more comfortable. The goal should be to have the leg splinted so well that the bird can't tell it has a broken leg!

# SPLINTING THE TARSOMETATARSUS

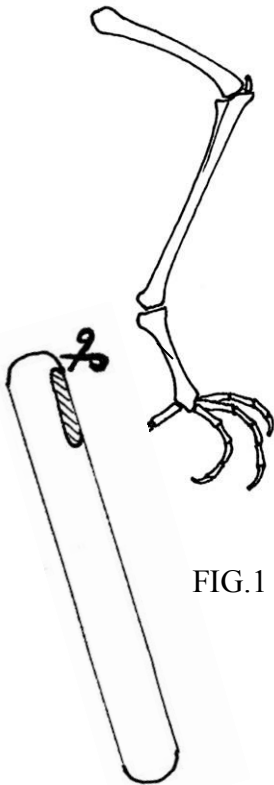


FIG.1

Tongue depressor

Thin coffee stir sticks are superior if available

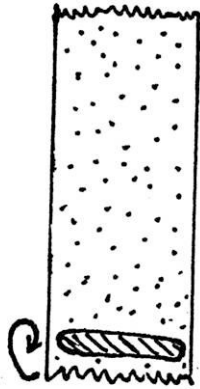


FIG.2 Wooden splint being rolled up in tape for padding




FIG.3

As shown in FIG.1, cut a flat piece of wood (such as from a coffee stir stick) to the size of the flat area of the outside of the tarsometatarsus. It must be thinner than the leg itself or it will be difficult to make the splint tight enough. Round any sharp edges and pad by rolling the wood up snugly in Micropore paper tape, or by securely taping a layer of telfa pad to cover all edges of the wood (FIG.2). Cut 2 strips of tape (FIG.3) in proportion to the drawing in FIG.4. For most small birds, tape should be around  $\frac{1}{4}$  inch wide.

Apply tape to the padded splint as seen in FIG.4. Seat the splint along the flat face on the outside (lateral) side of the tarsometatarsus, attaching the short end of the tape directly to the leg. Wrap the long end of the tape very snugly around the leg above and below the break, as shown in FIG.5. If bird is going to be getting its legs wet while healing, use a more waterproof tape.

If the leg has an open fracture, wrapping the tape this way leaves the fracture area open. This allows the application of a changeable dressing such as Hydrogel or Tegaderm and permits a clear view of the fracture site to monitor progress. You may desire to cover the area with a rectangle of telfa pad to keep out contaminants. Heavier birds (such as pigeons) may require the application of a redundant piece of splint placed at an angle to the original one, i.e. a duplication of the first support applied adjacent to the first that corrects a different angle of motion.

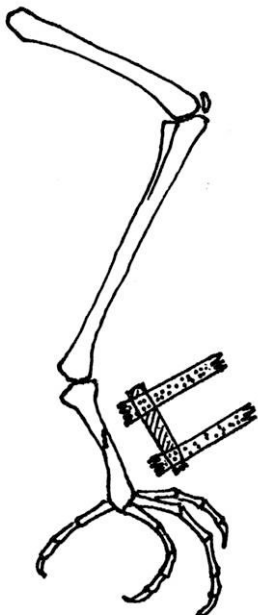


FIG.4

Tarsometatarsus fractures where the scales over the injury are broken and bloody sometimes result in a loss of blood supply to the foot, due to damage to the blood vessels. This will show as a gradual darkening of the skin and a lack of use or sensation in the foot, culminating in the foot drying out and falling off. These birds are candidates for euthanasia, as soon as it is apparent that the foot is dead. It is difficult to predict which bird will develop this problem, so the splint is often worth a try.

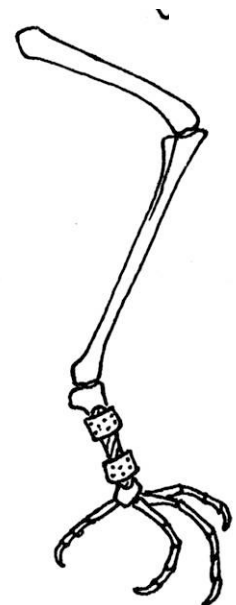
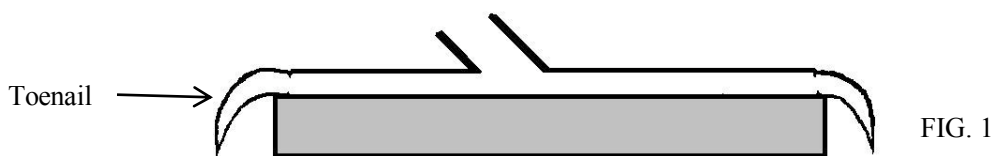


FIG.5

## SPLINTING THE FOOT—APPLYING A SHOE

Shoes are needed quite commonly in birds. They can be used to correct broken toes, toes curled into odd positions, holding the foot in a fist, and many other toe maladies. They can be quickly custom made for the individual bird, and like any splint on a small bird, need to stay on for 1-2 weeks.

A few pointers on materials: Use styrofoam or plastic (yogurt or ice cream container lids work well for tiny birds) as the foundation of the shoe. Cardboard gets soaked with water and droppings within minutes of putting the shoe on. Thin styrofoam from cheese packaging is thin enough for songbird shoes, but meat packaging styrofoam is too thick for most typical small patients except pigeons. Choose the material by the size of the bird's toenails (FIG.1). Ideally, the nail should have enough clearance to drape over the edge of the shoe without twisting the toe sideways from hitting the ground.



Conversely, if the shoe is too tall, the bird will tend to not put their whole weight on the foot and will not gain as much benefit from the shoe as they would if they were able to use the foot more normally. To secure the toes in position, use Micropore paper tape if possible. Many other tapes leave sticky residues that are hard to remove from the toes, or stick so securely that you risk breaking toes to get the tape off. A more waterproof tape can be helpful if you are applying the shoe to a bird that is going to be soaking its feet in water, such as a duck (see pgs 25-6). 3M Transpore tape works well for wet splints.

### BASIC SHOE DIRECTIONS FOR SONGBIRDS

You will need a piece of paper and a pen or pencil. Make the bird stand on the paper with its good foot. Mark the points where its toenails hit the paper (FIG.2). If the bird has two odd feet, use another animal matched for age and species to mark the paper. Transfer this information to the shoe material and cut it out with scissors (FIGS. 3 and 4). Put the bird back in its basket while you make the shoe. Post-its work well for the template since they will stick onto the final material.



FIG. 2. Using the good foot and a piece of paper, mark where the toenails hit the ground

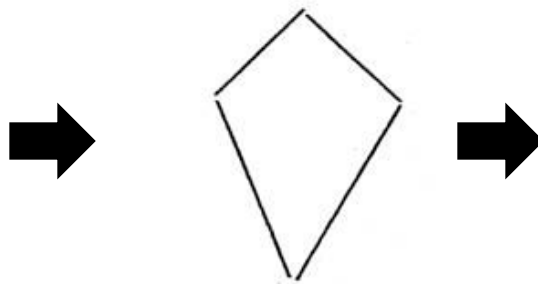


Fig. 3. Connect the dots and cut out the shape in the shoe material

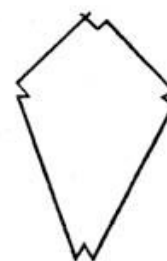
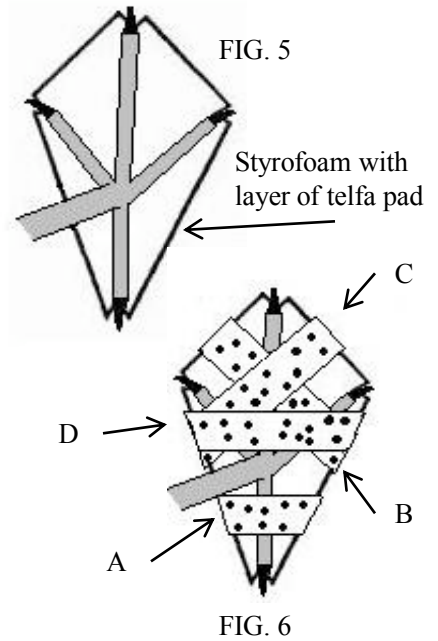


FIG.4. Trim out notches for the toenails to sit in



Next cut out a layer of telfa pad to cushion the styrofoam and attach it lightly with a glue stick; no need to cut out notches. You may need to use the flip side of your template if your patient is a species with asymmetrical feet. Keep track of which side of your shoe should be 'up'. Now cut 6-10 thin strips of Micropore paper tape about 2 inches long each (this often means cutting the tape lengthwise). Have a restrainer hold the bird with the leg extended away from the body. Tape digit #1 in position first (A), with the ends of the tape folding under the bottom of the shoe. Next, tape down the middle toe and the rest of toes into their respective positions (B, C, D). Add a few more strips of tape until you are confident the shoe is securely attached to the foot. Allow the bird to stand up and walk around its basket for a few minutes to see if it is standing with its feet flat on the ground.



### TROUBLESHOOTING

**Standing with shoe sideways:** try adding a snugger piece of tape across the top of the foot (D), flattening it towards the shoe surface.

**Still standing with shoe sideways:** add a tape connection between the tarsometatarsus and the bottom of the shoe to correct the undesired motion.

**STILL standing with shoe sideways:** reapply shoe, with greater attention to applying even tension to all toes.

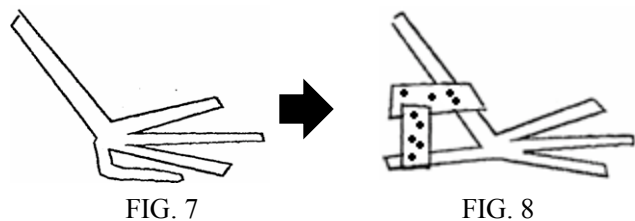
Remove the shoe in 1 week. If the problem is still evident, reapply shoe for another week (just clean off the Styrofoam and change the telfa pad—no need to make another shoe) Always remember to monitor your patient for stress, and allow the bird to relax in its basket as necessary during shoe application.

### ODDS AND ENDS

**Long-legged wading birds:** A partial shoe that just supports the foot joint extending part-way out the base of each toe usually provides adequate support while still allowing the bird to perch with the toes. Toes can be splinted individually if necessary.

**Toe bent side to side more than taped shoe can straighten out:** add a tape-wrapped tiny piece of toothpick or similar item to the side of the toe and snug the toe up to it. Tape the support in place alongside the toe.

**Digit #1 tucked under the foot:** this problem does not usually need a whole shoe to correct. Using one or two thin strips of Micropore paper tape, tape the toe in the proper position (FIGS. 7 and 8). Leave tape on for a week. Adjust the angle to the proper angle for the species (look at the good leg or another animal). Very few birds have a 90 degree angle between their tarsometatarsus and the ground.



# Mallards: walking/swimming splint for TMT fractures

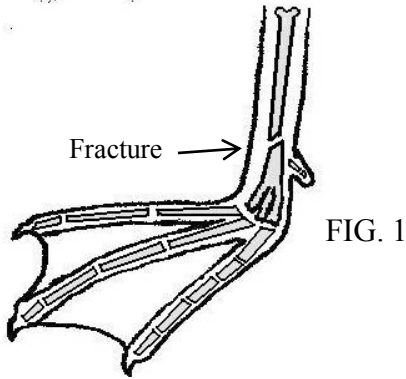


FIG. 1

Roll splint in  
Transpore tape to  
pad

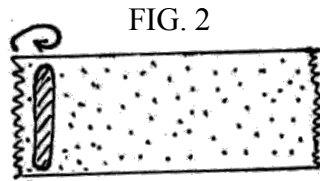


FIG. 2

Position padded  
splints on outside and  
front of leg, avoid  
inside of leg, tape  
securely esp at (A)

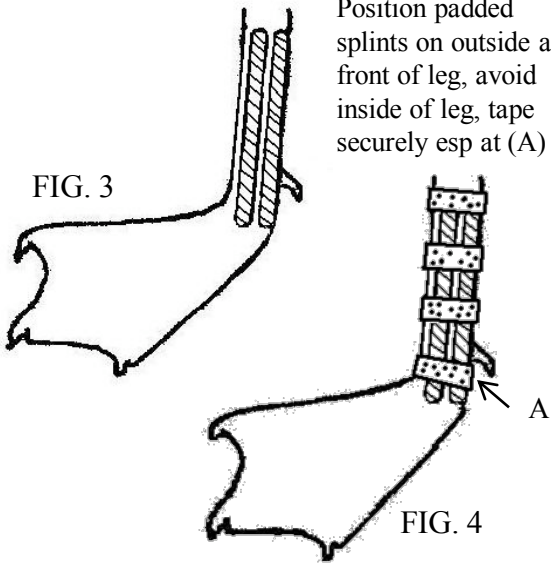


FIG. 3

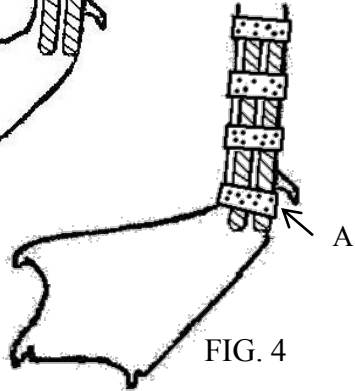


FIG. 4

A combination of a shoe and a tarsometatarsus (TMT) splint works well for ducks with closed TMT fractures. The TMT in ducks hit by cars often breaks near the base of digit #1, with some fractures occurring at the base of the TMT at the partially fused metatarsal bones. On x-ray, the foot end of the TMT sometimes looks like a broken pile of shards if the metatarsals are broken loose from each other, but may heal fine with application of this splint.

Begin the splint by stabilizing the fracture as described previously for tarsometatarsal fractures, with two pieces of thin wooden splints rolled in tape for padding. In order to make this a waterproof splint use 3M Transpore tape, which holds up well in the water but is permeable to oxygen. Paper tape will become worthless quickly in the water. Apply the padded wooden splints on the lateral to front sides of the leg, adjacent to each other. Avoid the inside of the leg to avoid compressing the medial metatarsal vein. Tape securely along the length of the TMT, and be sure to tape snugly below digit #1 with a thin strip of tape between digit #1 and the bottom of the foot.

Next make a shoe by tracing the shape of the standing webbed foot shown in FIGS. 5 and 6. Meat or cheese packaging foam is a good thickness for duck shoes, thin take-out packaging from restaurants may need a double layer. Apply the tape directly to dry skin and tape the shoe on securely with the toes positioned for standing as shown in FIG.7.

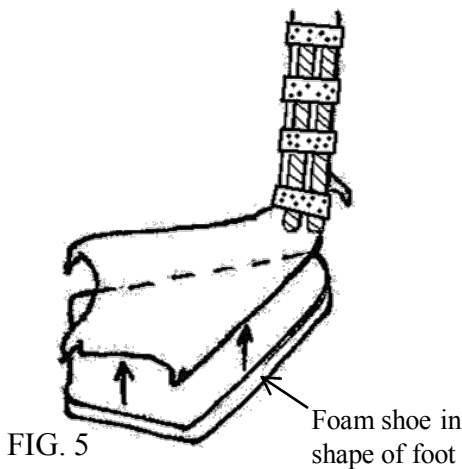


FIG. 5

Foam shoe in  
shape of foot

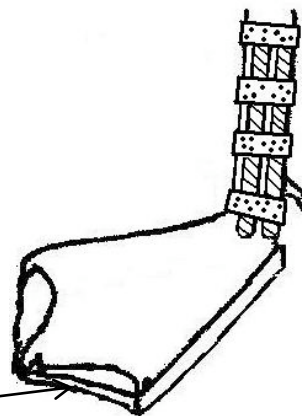


FIG. 6

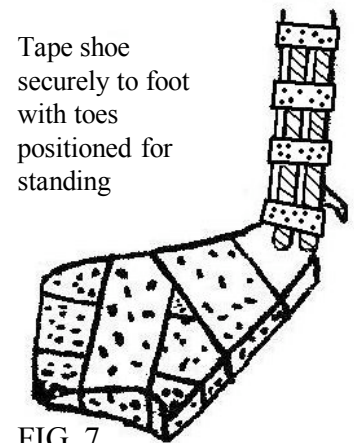


FIG. 7

Tape shoe  
securely to foot  
with toes  
positioned for  
standing

## Mallards: walking/swimming splint for TMT fractures continued

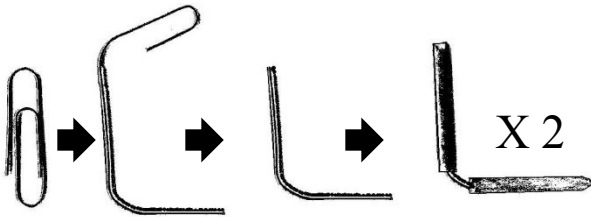


FIG. 8. Paperclips trimmed and padded by rolling in Transpore tape. Need two.

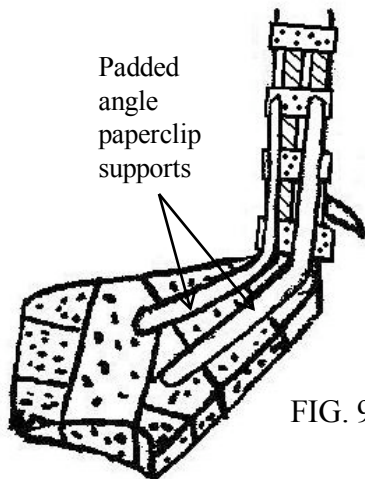


FIG. 9

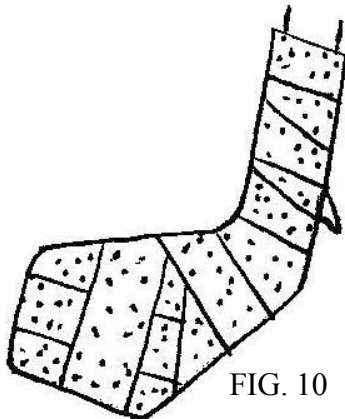


FIG. 10

Create padded paperclip angle connectors by trimming and shaping paperclips as shown in FIG. 8. Adjust the bend to whatever angle will fit between the toes to attach to the front face of the TMT as shown in FIG. 9, to allow for a normal standing position. Use the good leg to choose this angle. The angle varies somewhat between birds—some birds have a near 90 degree angle, some are less sharp than this. Position one angle between digits #2 and #3 and one between #3 and #4. Tape one end snugly to the front side of the tarsometatarsus and tape the other end to sit parallel to and between the toes.

Wrap the whole shebang securely with Transpore tape as shown in FIG. 10, but leave the toenails and toe tips exposed if possible so you can monitor the foot for swelling. Transpore tape is somewhat see-through so some monitoring is possible through the tape. The duck may be up and walking or swimming with the leg within a day or so. If the bird's waterproofing is adequate for swimming, allow access to water, as floating can make the bird much more comfortable and allow for normal feeding.

Daily, re-examine the splint for tape loosening and apply more tape as necessary. After one week, remove the splint; if any movement is felt at the fracture site, reapply for another week. You may not need to reapply the shoe and angle.

If the foot is very swollen and appears discolored, the presence of a pain response to pinching the toe tips is a good indicator that the bird still has a good chance of recovery. Lack of response to pinching is a bad sign as ducks usually are more straightforward in their responses than other species may be.