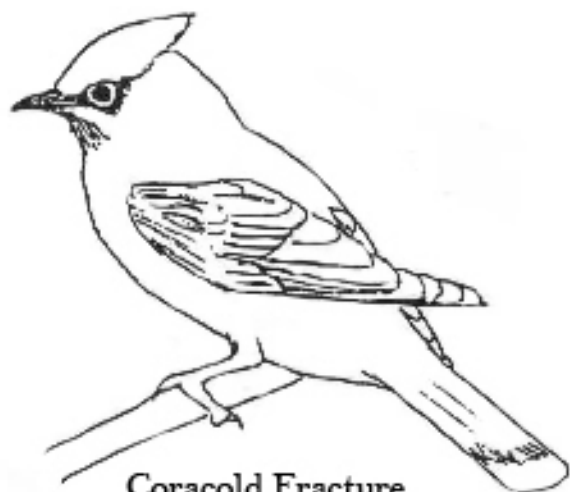


Recognizing Fractures of the Wing

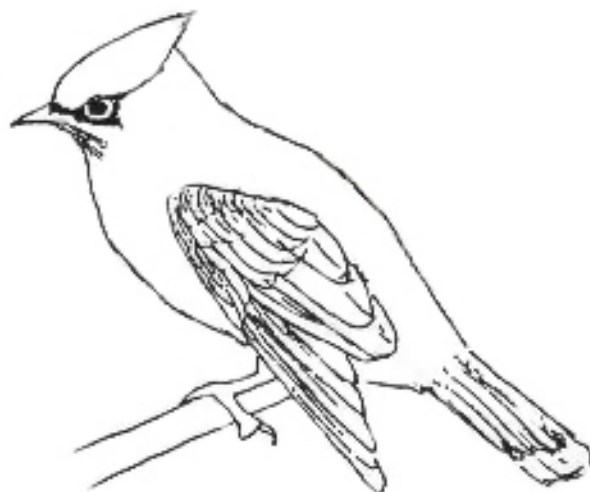Courtesy of Leah Schimmel




**Humeral Fracture
or injury to elbow joint**



**Coracoid Fracture
or injury to shoulder joint**



**Carpal or Metacarpal fracture
or injury to wrist joint**



Radial /Ulnar Fracture